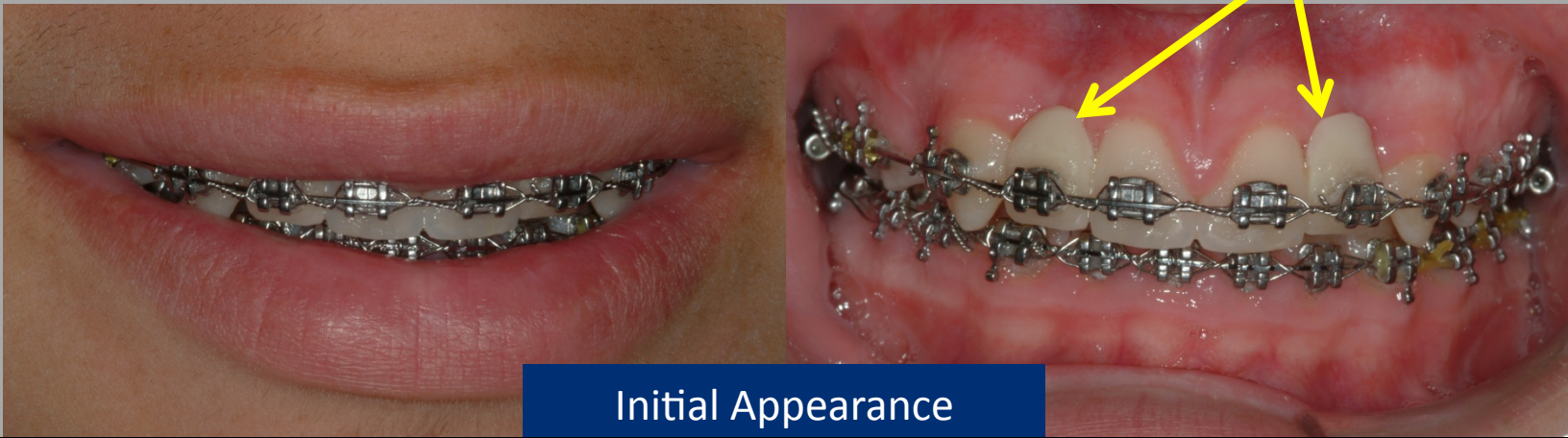
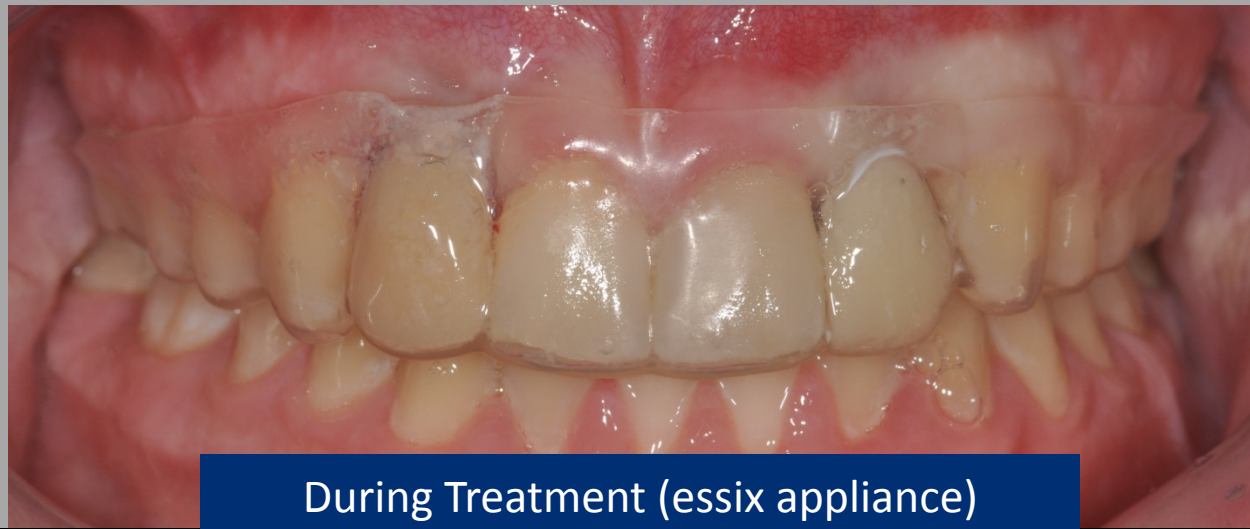
# Congenitally Missing Teeth #7 & #10 Replaced with Implants and Crowns

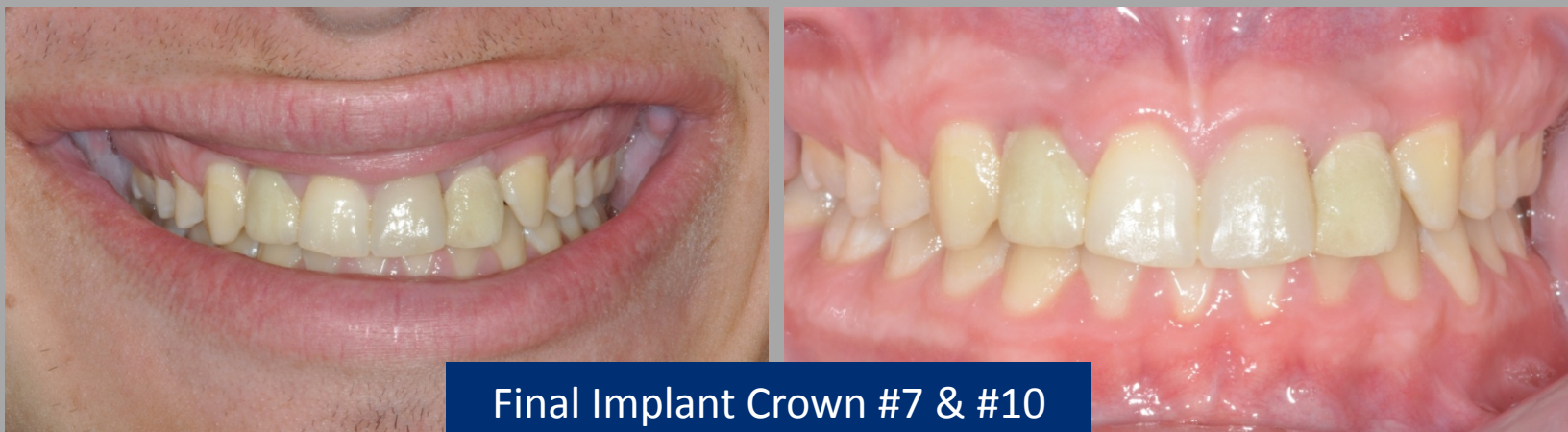
**Background:** SA did not have permanent lateral incisors #7 & #10. As a result, he needed implants to replace these teeth.



Initial Appearance



During Treatment (essix appliance)



Final Implant Crown #7 & #10

**Testimonial:** "So glad to have my teeth before the prom and graduation!  
Thanks Dr. Kubikian!" -SA, Ocean City, NJ