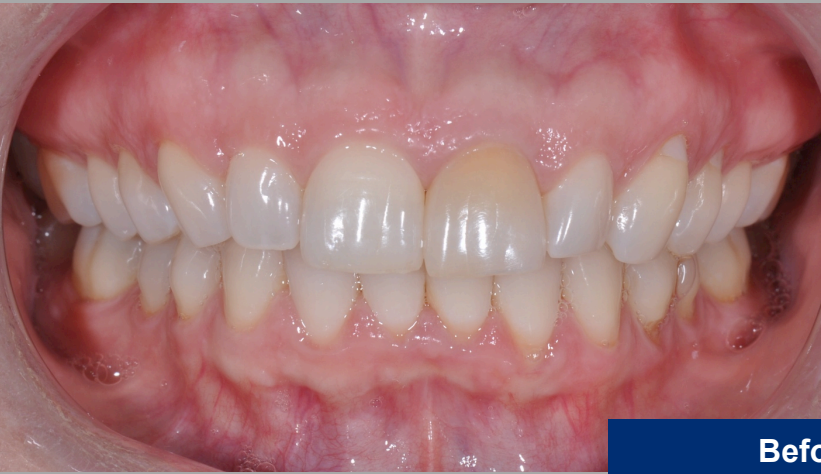
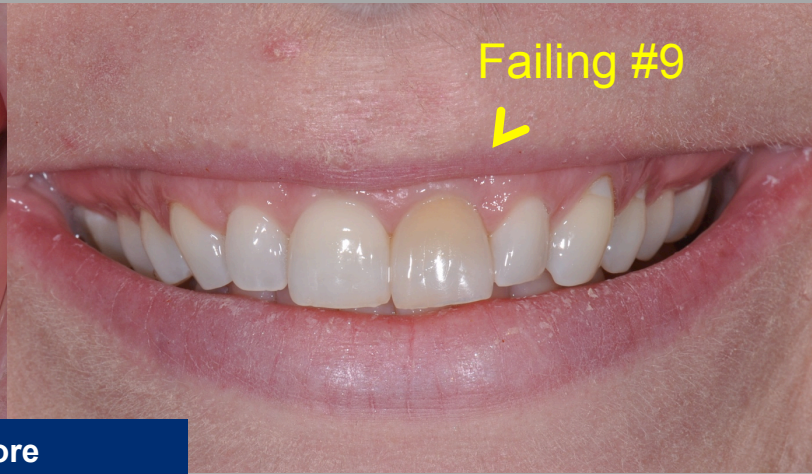
Implant #9 with Crown

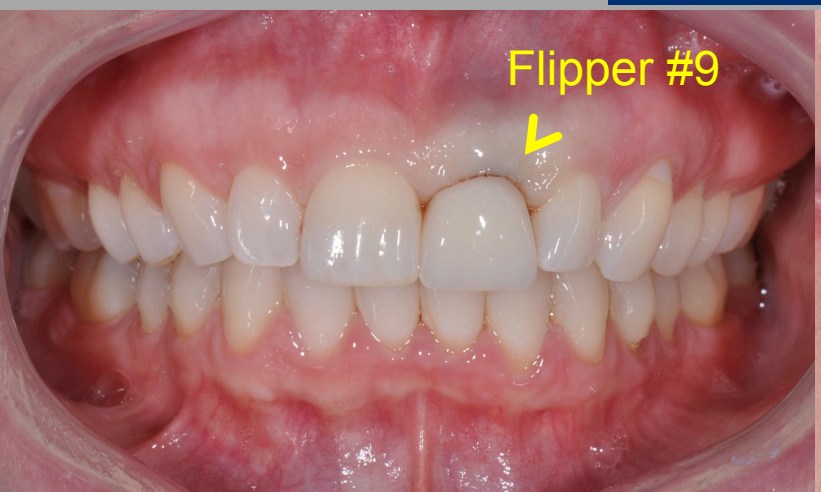
Background: HW has advanced internal resorption on tooth #9 with associated discoloration.



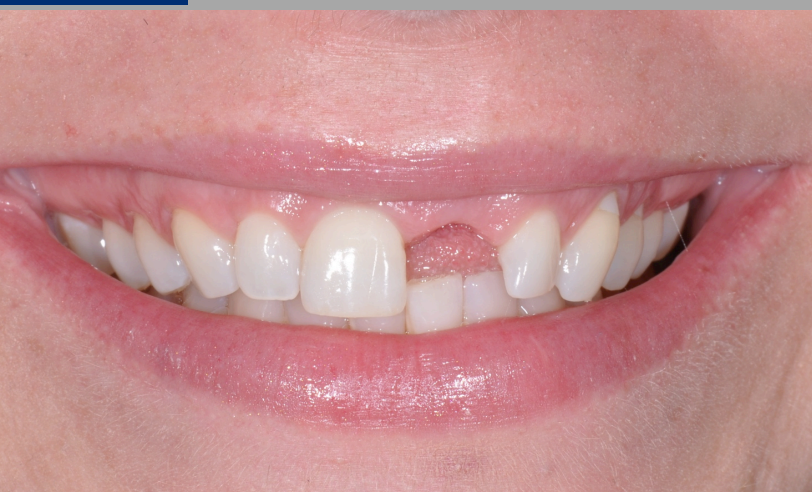Before



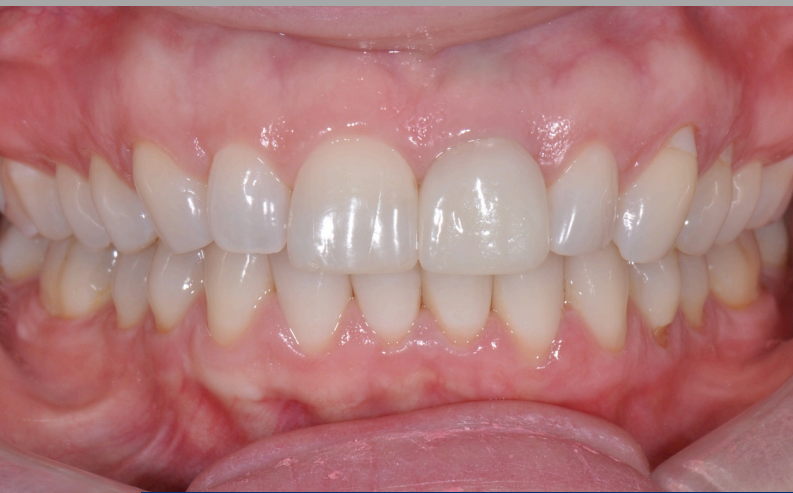Failing #9



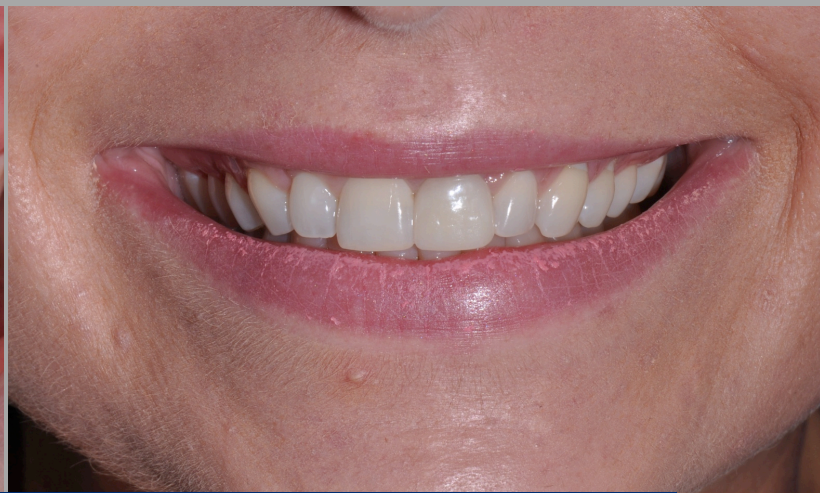Flipper #9



A flipper was used to temporarily replace #9 during implant integration



Final Implant Crown #9



Testimonial: "Wow, thank you SO much!!!"

H.W. - West Deptford, NJ