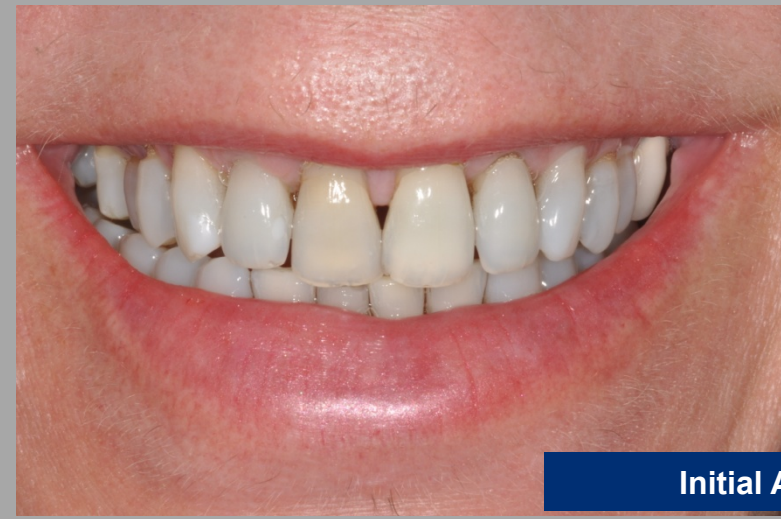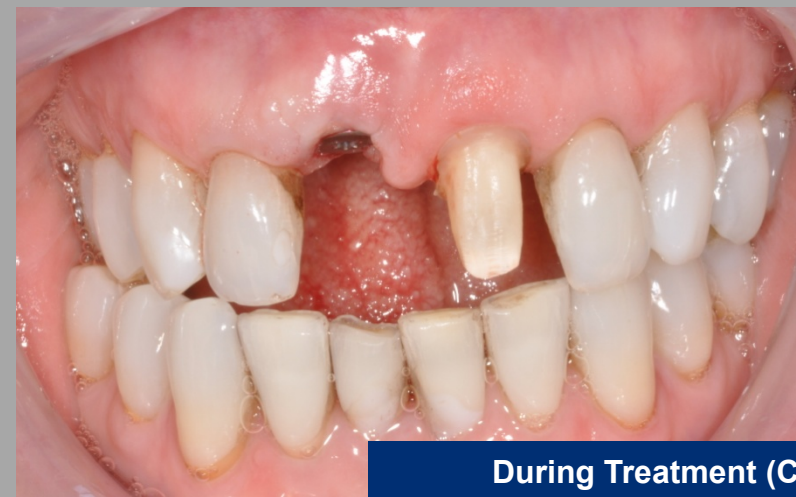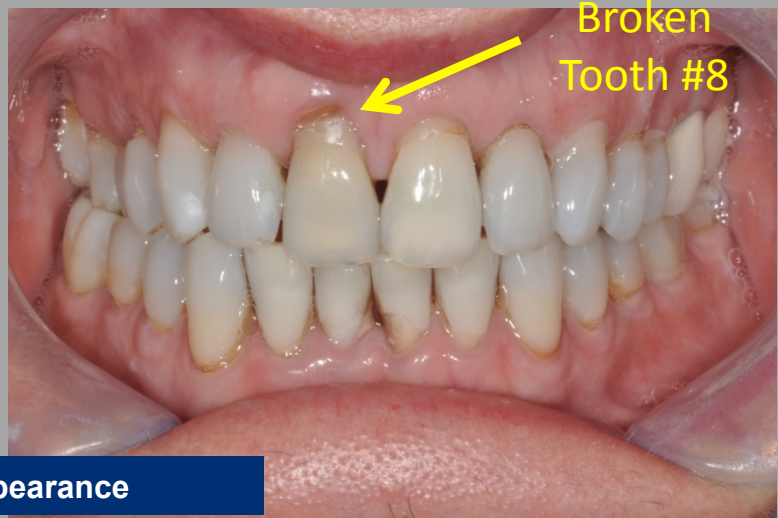


# Implant #8 with Crown

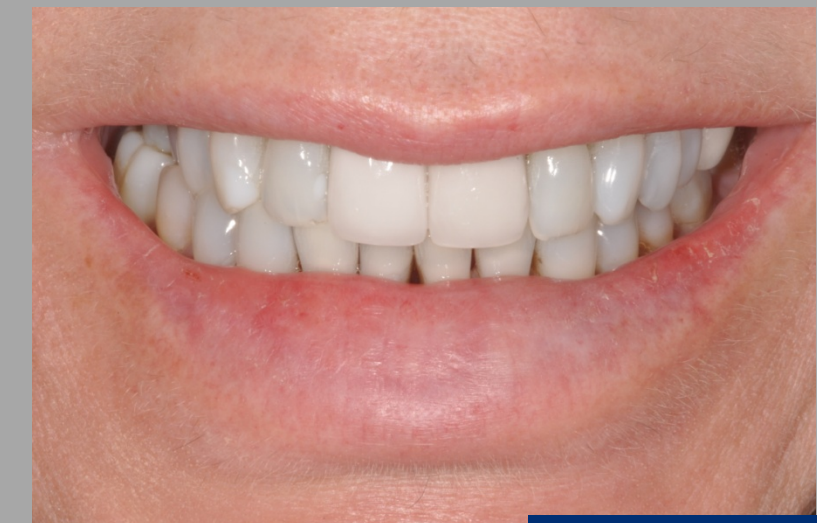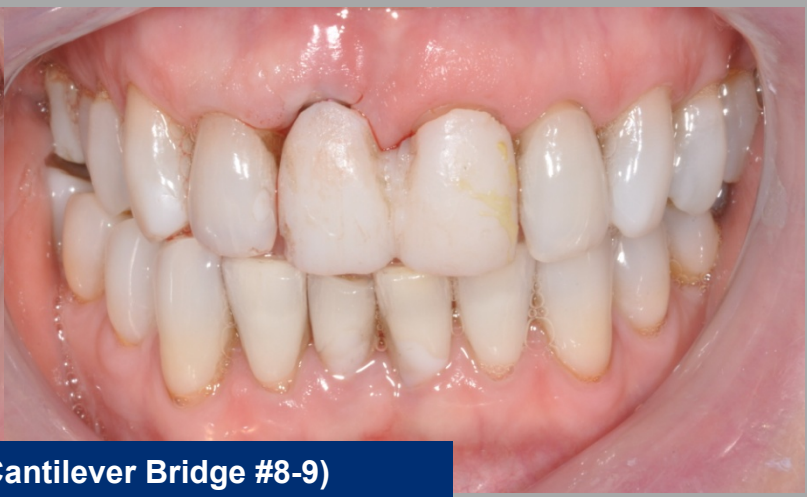**Background:** AS fractured tooth #8 and wanted a dental implant, but did not want to wear a removable appliance as a transitional restoration. As a result, her other front tooth was used to support the temporary #8 while implant #8 integrated.



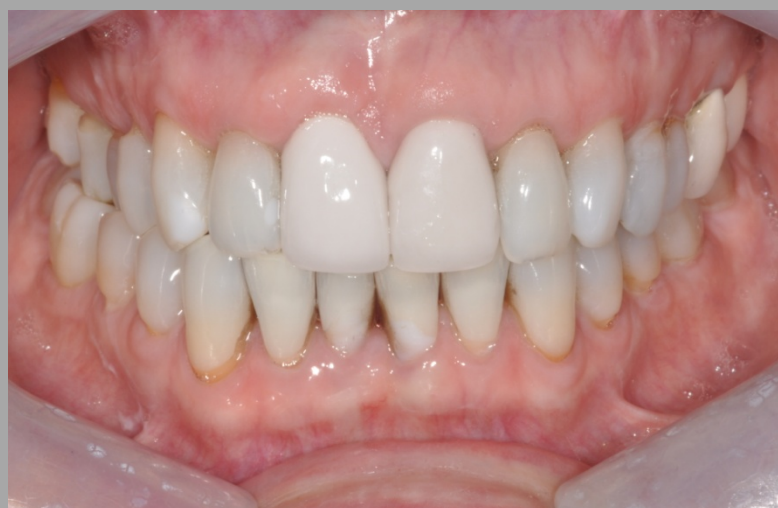Initial Appearance



During Treatment (Cantilever Bridge #8-9)



Final Implant Crown #8



**Testimonial:** "I drove 45 minutes for my appointments each time.... I'm thrilled with the end result, as you promised!" – AS, Ocean City, NJ