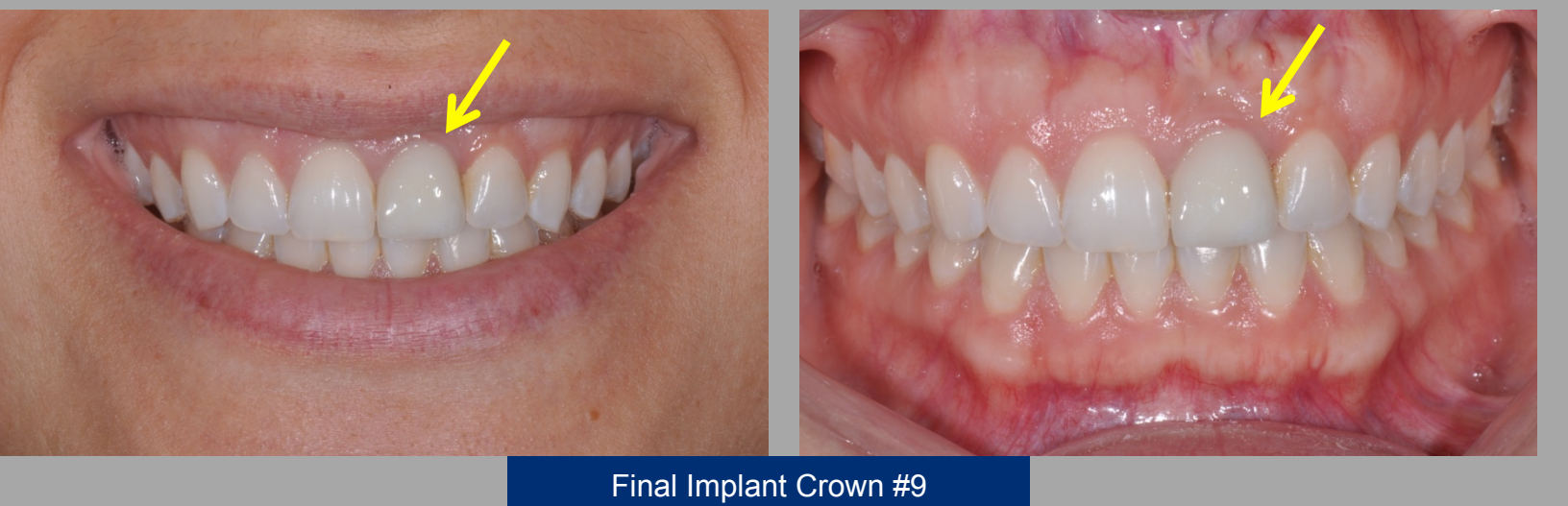
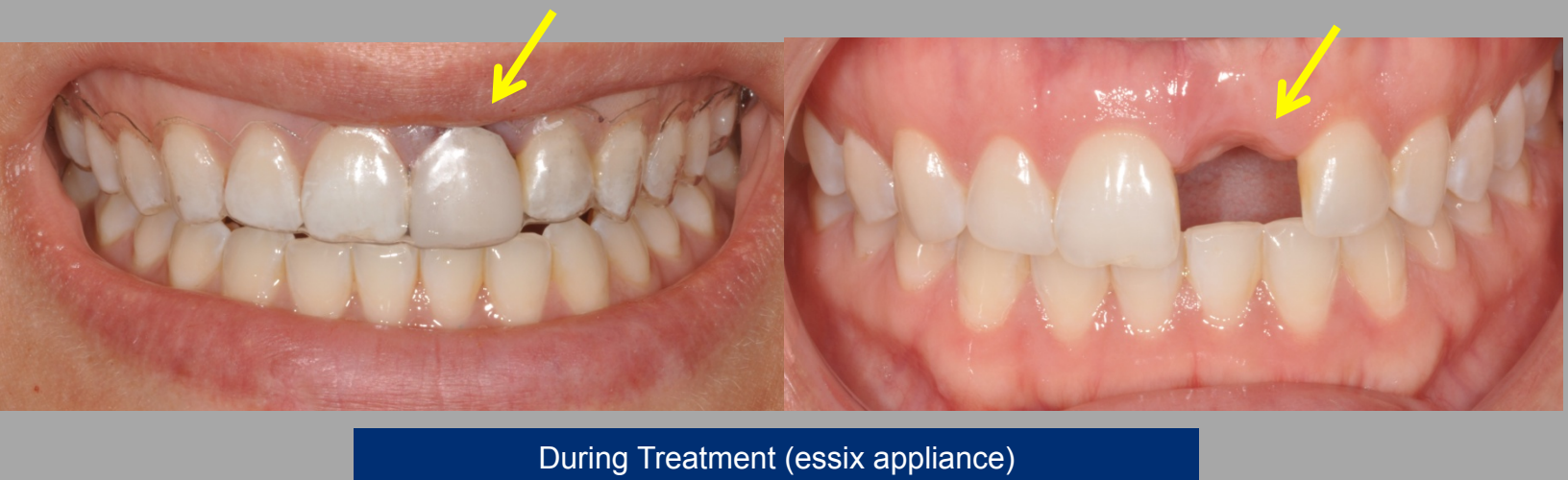
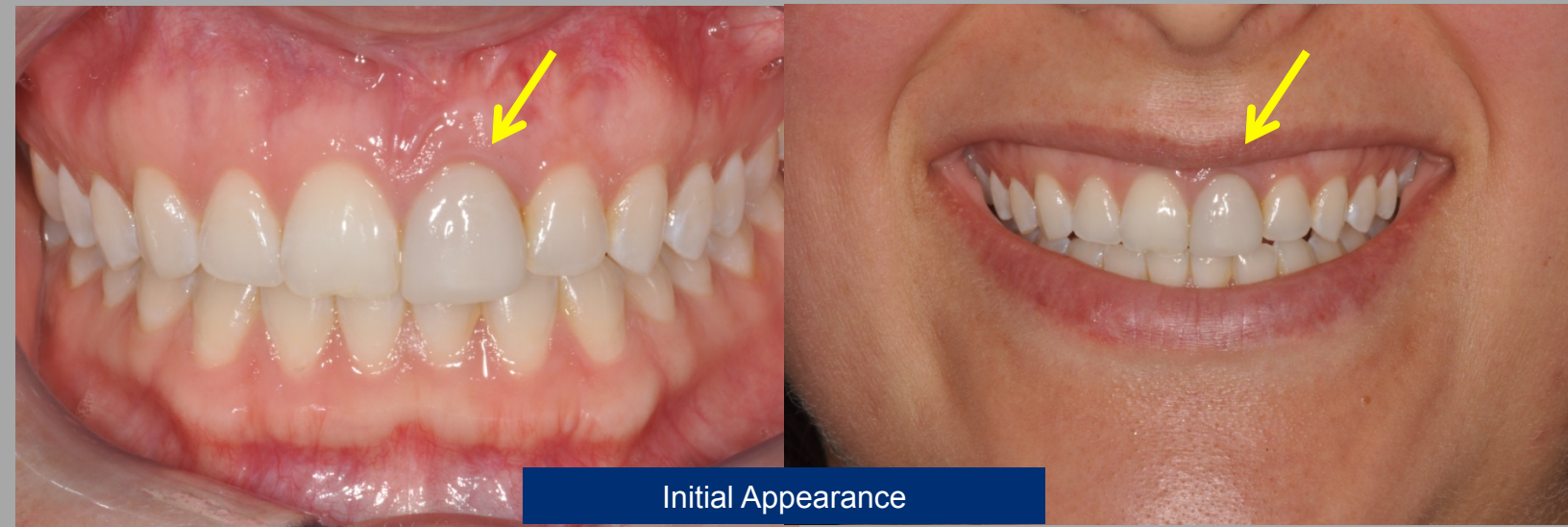
Implant #9 with Crown

Background: AM required the removal of tooth #9 due to previous root canal and infection. She desired a dental implant.



Testimonial: "I think that the process was much easier than expected and I was guided through the process well. I'm very pleased with the end result!" AM - Wenonah, NJ