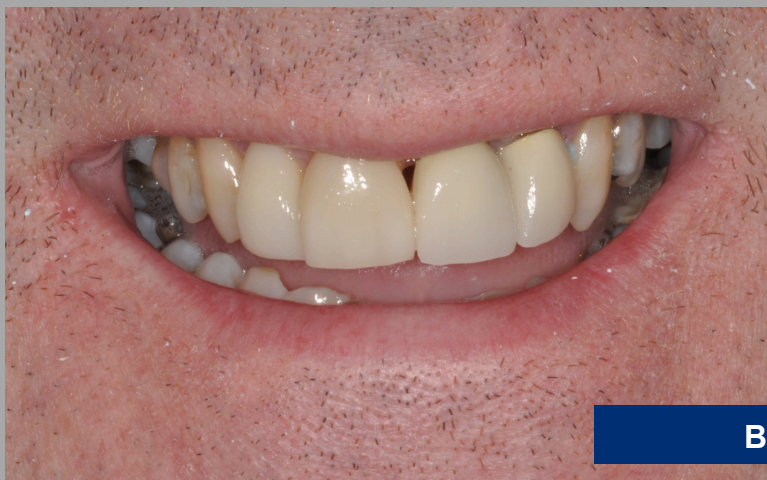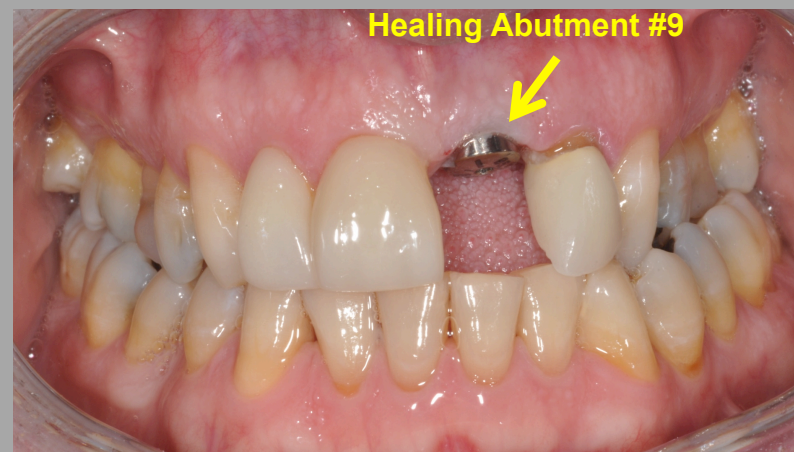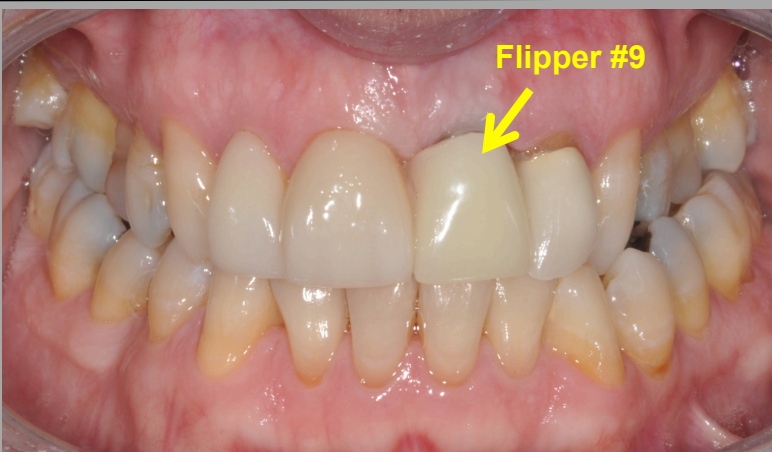
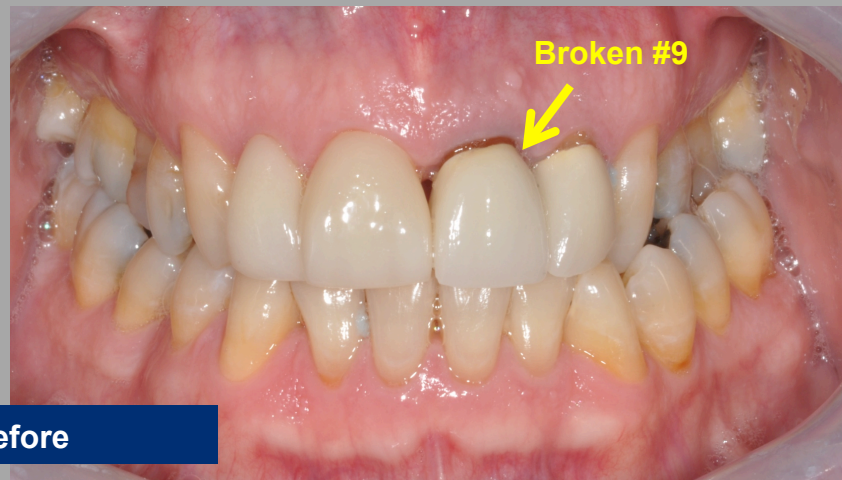


Implant #9 with Crown

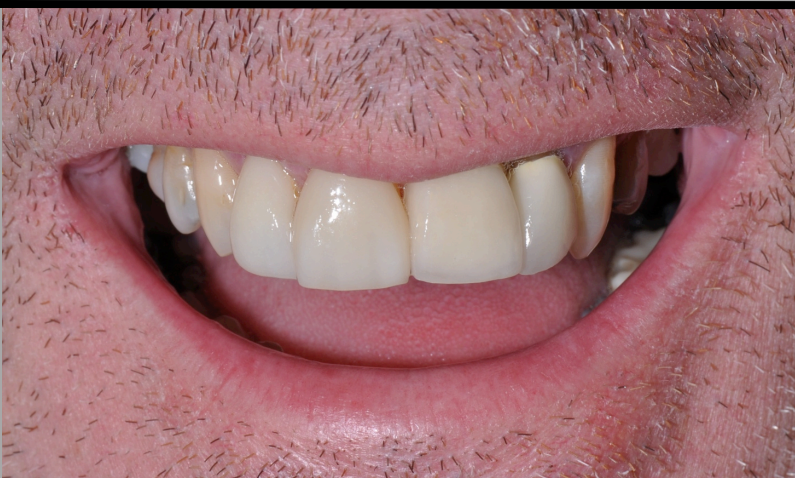Background: JQ suffered trauma 30 years ago on his front tooth and recently fractured his front tooth eating dinner. He wants to replace it with a dental implant.



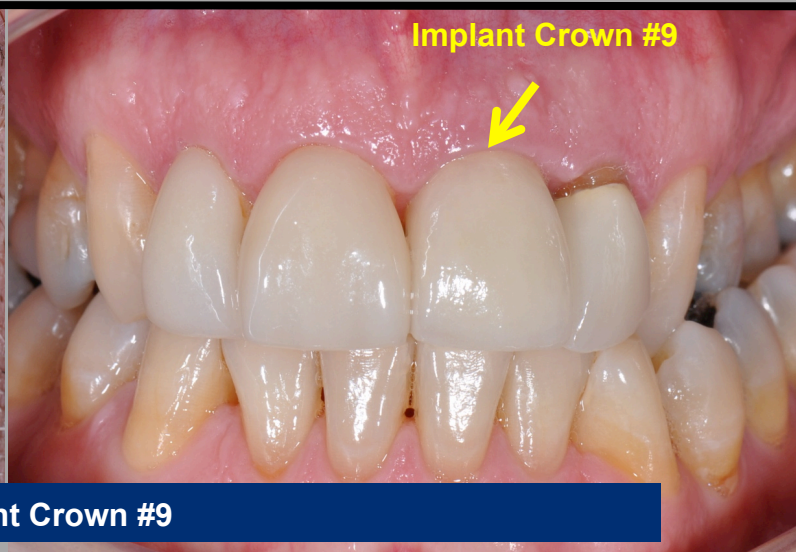
Before



A flipper was used to temporarily replace #9 during implant integration



Final Implant Crown #9



Testimonial: "“I was a little bit nervous about having an implant done, but afterwards, it was really worth the time. I had no pain at all. I have to say that I really love the feel of this tooth. It is so much better than what I had before. And that’s the absolute truth, it’s like a real tooth”

J.Q. - Mullica Hill, NJ