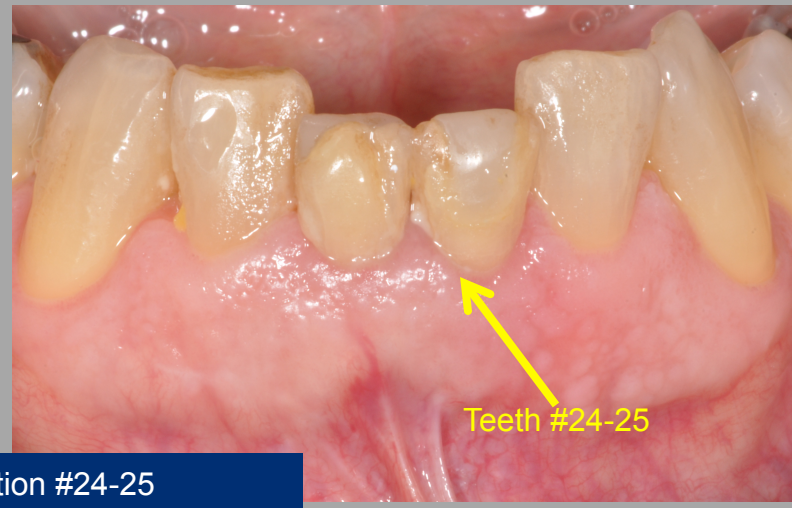
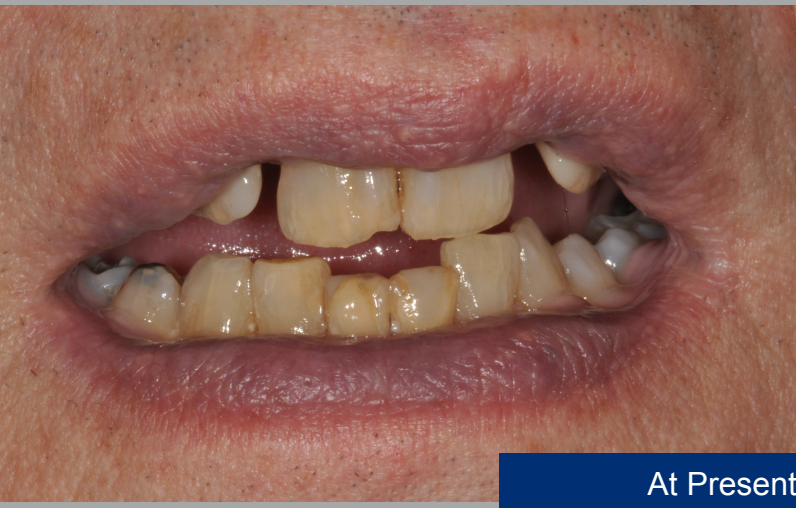
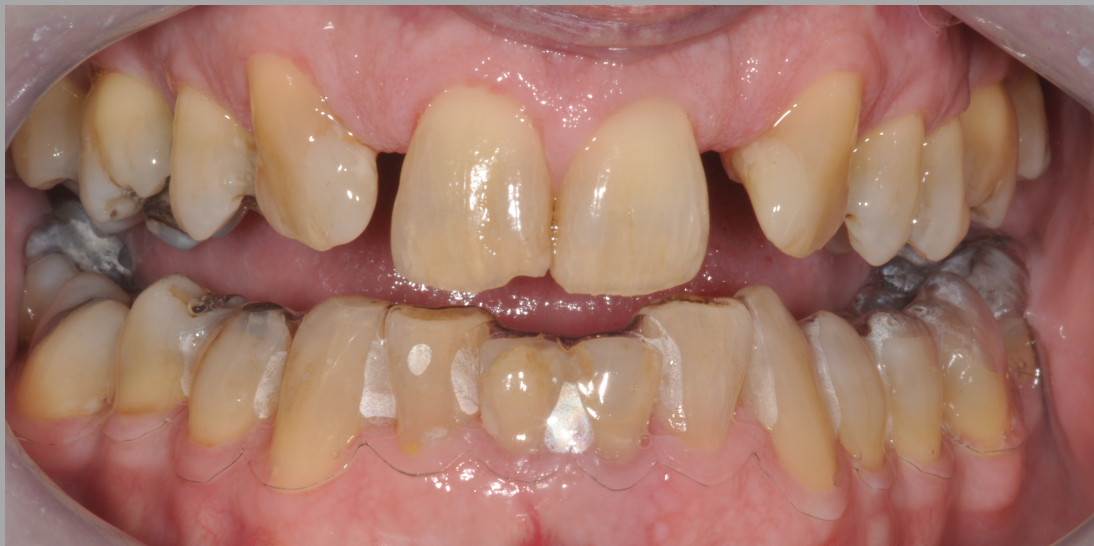
Implant #25 with Crowns #24-25

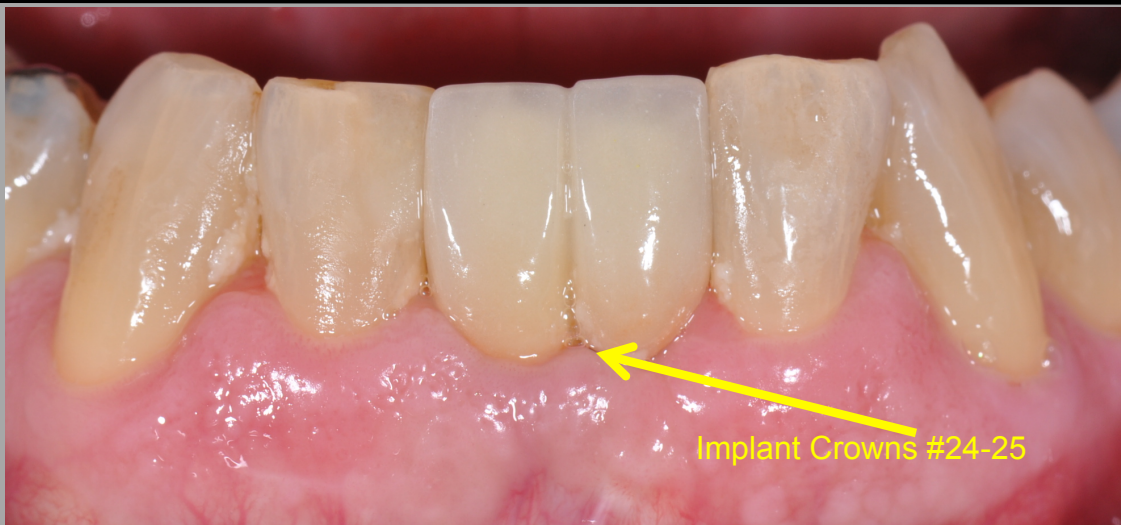Background: HG had two teeth which could not be saved. Since the lower anterior teeth have.



At Presentation #24-25



Patient is wearing an essix appliance during integration of implant #25



Final Implant Splinted Crowns #24-25

Testimonial: "I found that it was easy enough, just time consuming. I would do this again and it is what I expected; functional and esthetic" HG - Pitman, NJ