

CLINICAL CASE REPORT APRIL 2016

SOUTH JERSEY PERIODONTICS & DENTAL IMPLANTS, LLC

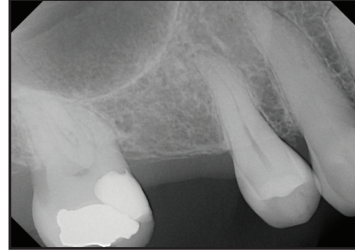
DANIEL KUBIKIAN, DMD

340 Egg Harbor Road • Sewell, NJ 08080

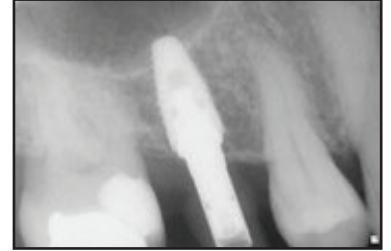
Background: Laura presented with interest to replace missing tooth #3.

Initial Findings: Upon placement of implant #3, a digital scan body impression was taken before she left the office

Pre-Operative Photographs



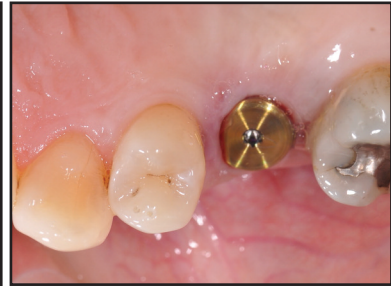
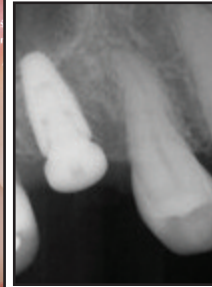
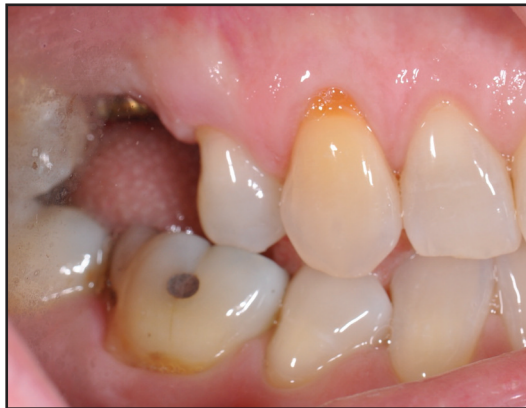Initial Visit with Missing Tooth #3



Radiograph with Implant Scan Body
(at the time of implant placement)

Steps:

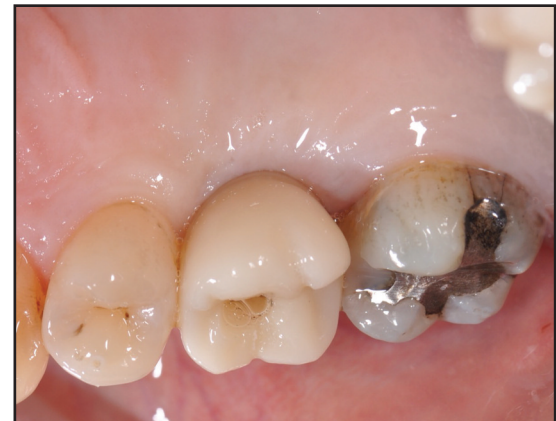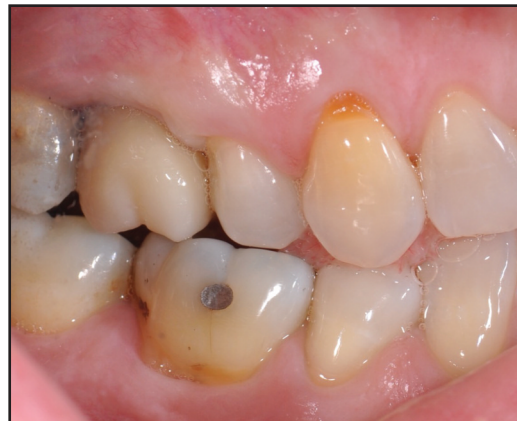During the osseointegration period, the laboratory fabricated the final screw retained restoration so that the restorative dentist would be able to deliver the final crown immediately after stage II surgery was performed at my office.



Healing Abutment Placed @ 10 weeks

Case Conclusion:

“When applicable, an implant scan body impression at the time of surgical implant placement can allow the laboratory to fabricate the final screw retained implant restoration during the osseointegration period. This can reduce the overall treatment time, significantly lessen the restorative laboratory fees (no need for impression copings, implant analogs, pouring models) and deliver the final crown with shade matching capability.”



Final Implant Crown #3

“I hate impressions! I’m thrilled that my restorative dentist can place the final crown within 24 hours (after stage II surgery) and I don’t have to miss another day of work.”

Patient

“The process was a very streamlined process and allowed for an easy flow between the surgical and restorative components. Very accommodating for patients with busy schedules and allows the doctor to meet high expectations.”

General Dentist - Dr. Jason Raines, DMD