

CLINICAL CASE REPORT APRIL 2016

SOUTH JERSEY PERIODONTICS & DENTAL IMPLANTS, LLC

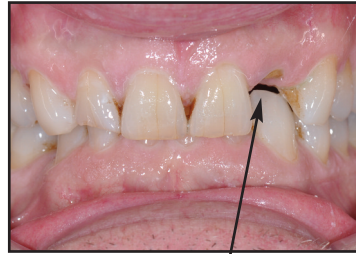
DANIEL KUBIKIAN, DMD

340 Egg Harbor Road • Sewell, NJ 08080

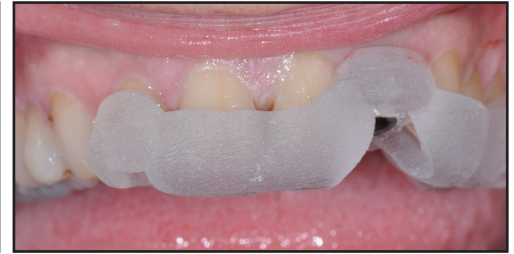Background: PN presented with broken tooth #10 and wanted to have an immediate tooth replacement options which was not removable.

Initial Findings: Based on the 3D cone beam scan, the broken tooth #10 had sufficient bone to perform computer guided implant surgery for the purpose of immediate implant placement and immediate loading of the implant #10.

Pre-Operative Photographs



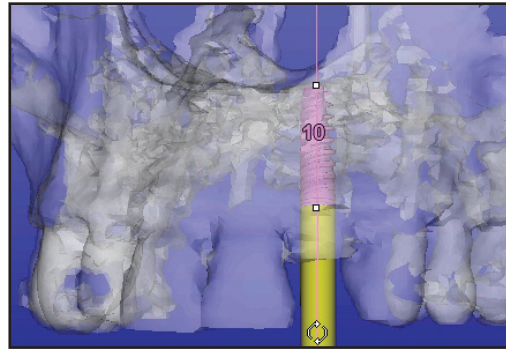
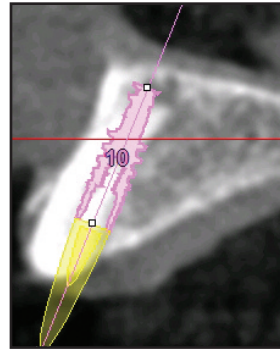
Initial Visit with Broken #10



Computer Generated Surgical Guide

Steps:

After fabrication of the surgical guide from the 3D software, the guide allowed precise implant placement and loading of a premade customized screw retained provisional with shade matching capability from the Trios digital scanner.



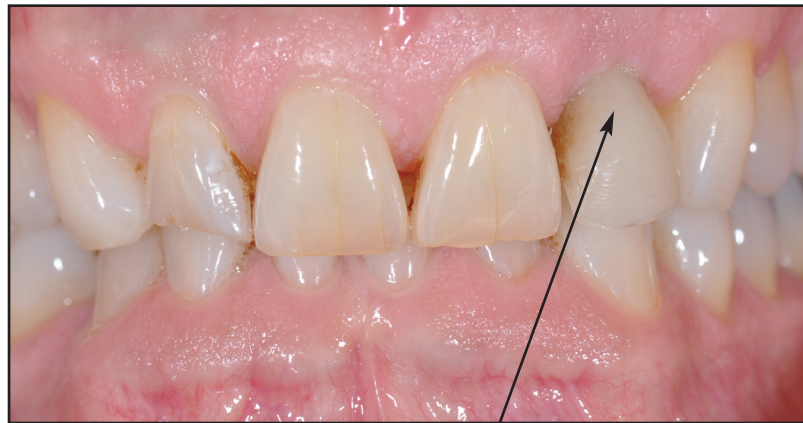Computer Planning Software



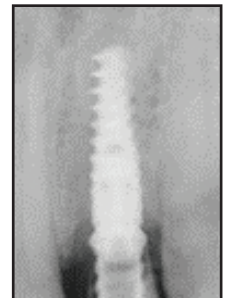
Computer Generated
Implant Provisional
Crown #10

Case Conclusion:

When applicable, computer guided implant surgery in combination with prefabrication of the immediate loading provisional can allow for **reduced pain, treatment time and costs** for the patient to receive an immediate provisional restoration on the day of extraction with implant surgery.



Final: Implant #10 Immediately Loaded



"I just went through a 7 month procedure in 90 minutes. This technology is the best thing going and I recommend this to anybody. So glad my doctor referred me here. I can't wait to see my doctor for the final crown on my implant!"
Patient - PN

"The beauty of this was that he was able to be perfectly comfortable throughout the healing process because he didn't have a flipper."

General Dentist - Dr. Richard MacFeeters, DMD